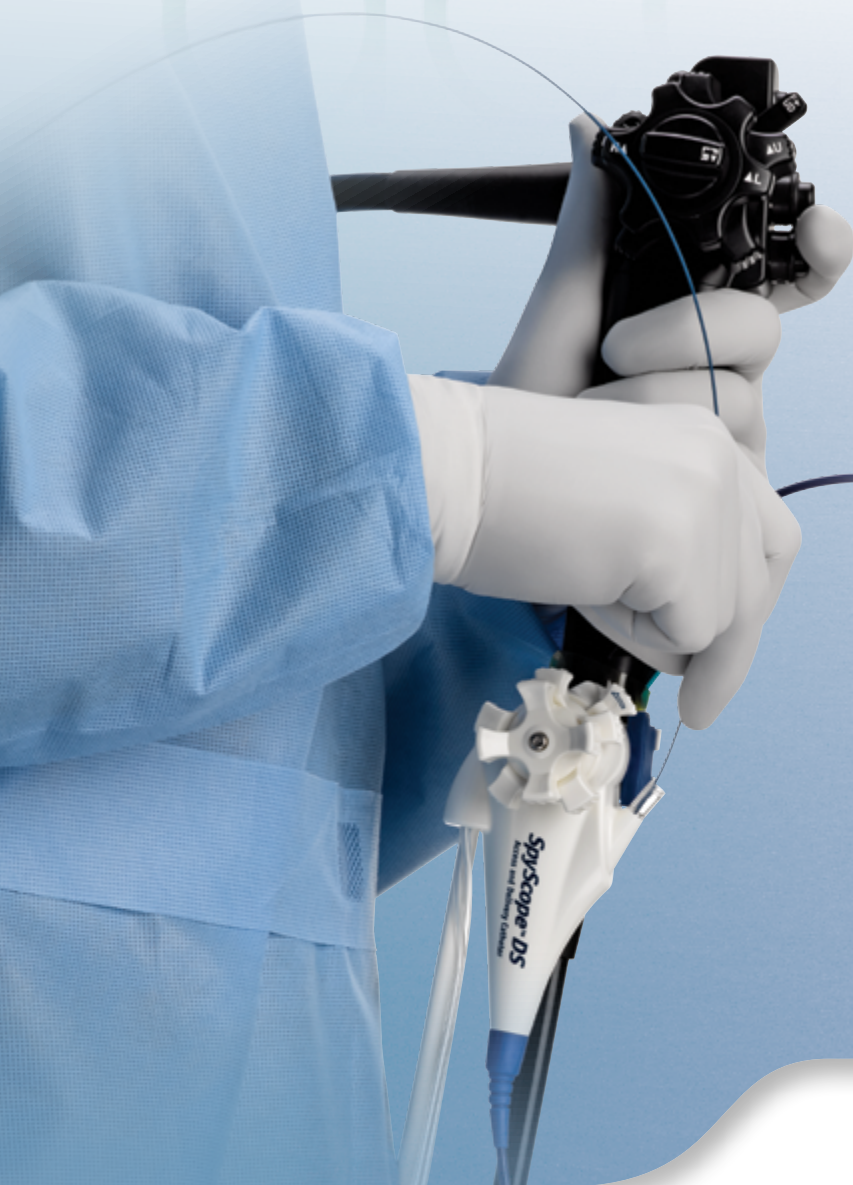


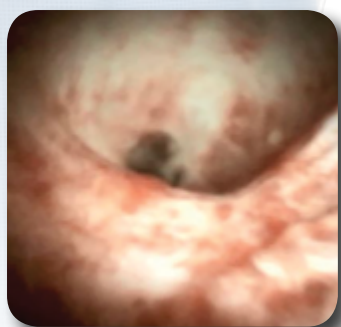
access

ENHANCING PATIENT OUTCOMES. DELIVERING TOTAL VALUE.™



SpyGlass™ DS Direct Visualization System

Once again, changing what's possible in cholangioscopy



A Message From Dave Pierce

As the business of health care changes, it's our job to evolve with our customers. We continually seek to find new and better ways to support them as they develop new models to deliver patient care while managing costs. It's about providing solutions – through product innovation, services, advocacy and more.

Since its introduction in 2007, the SpyGlass™ Direct Visualization System has dramatically changed the practice of cholangioscopy. The SpyGlass Single Operator Cholangioscopy System was truly one of the most innovative GI devices ever developed. It's been used in more than 75,000 patient procedures around the world, and over 300 articles have been published documenting its value in diagnosing and treating pancreatico-biliary diseases.



Employees at Boston Scientific's facility in Galway, Ireland, where the combined heat and power plant has reduced the amount of greenhouse gases going into the atmosphere each year by more than 3,000 metric tons.

Innovation continued, and in January the new SpyGlass DS Direct Visualization System received 510(k) clearance from the FDA. The new system provides superior imaging, far greater resolution and a 60 percent wider field of view than the first SpyGlass System. It's already a game changer. Physicians performing some of the early cases report seeing things they've not been able to see before, enabling them to detect, diagnose and treat sooner. (Read about the new system on p. 2.)

Organic innovation isn't the only path to developing new products and enhancing existing technologies. The acquisition of Xlumena allows Boston Scientific to expand its endoscopic ultrasound (EUS) capability with the addition of a therapeutic EUS technology (p. 6). The next-generation HOT AXIOS™ Stent and Delivery System incorporates cautery into the delivery of the AXIOS™ Stent and is currently available in Europe for facilitating transgastric or transduodenal endoscopic drainage of a pancreatic pseudocyst or the biliary tract.

When it comes to services, there is clearly no one formula that works for all. Our customers' needs are as unique as their geography and the patient population they serve. It's why we take a custom approach to many of the services we offer — supply chain, benchmarking for performance optimization and others. As the implementation of the Affordable Care Act took shape and hospitals began taking a more holistic approach to patient management, we recognized the need. Today, we're piloting new services to address issues that impact procedural efficiencies and patient management.

We regularly collaborate with gastroenterology societies and government agencies to advocate for appropriate reimbursement and to address regional and national reimbursement challenges. It's important work that can have a significant impact on a customer's financial health. We appreciate being recognized by Dr. Glenn Littenberg for our work in helping to increase Medicare reimbursement for ERCP and GI stenting (p. 13).

This issue covers a wide variety of information about our products, services and support. Our Resolution™ Clip received CE Mark approval in March and it is the first clip in the U.S. to receive clearance for a prophylactic indication (p. 5). Boston Scientific was recently recognized for its packaging innovation by two prominent associations (p. 11). To date, 12 of our facilities have completed certification to the ISO 14001:2004 certification Environmental Management System standard (p. 10). And through our Close the Gap initiative, we continue to address health disparities, promote early screenings and generate awareness for diseases such as pancreatic and colorectal cancers (p. 7 and back cover). I encourage you to visit www.preventcrc.com to learn how to get involved.

A handwritten signature in black ink, appearing to read 'DAP', written in a cursive style.

Dave Pierce

Senior Vice President, Boston Scientific
President, Endoscopy Division

Inside This Issue

Articles

- | | | | |
|------------------------------------------------------------------------------------|--------------------------------------------------------------------------------------------|-------------------------------------------------------------------------------------|------------------------------------------------------------------------------|
|  | 2 New SpyGlass™ DS System Brings a Sharper Focus to Cholangioscopy |  | 8 China Summit Marks the Start of Physician Training Program |
|  | 4 An Interview with Director of Boston Scientific Supply Chain Solutions, Bryan Gilpin |  | 9 Screenings are Part of Campaign to Deliver Care to Remote Region of Brazil |
|  | 5 Resolution™ Clip is First Hemostasis Clip to Receive Clearance for Prophylactic Clipping |  | 9 New Online Tools for Patients and Physicians |
|  | 5 Largest Study Published on WallFlex™ Fully Covered Esophageal Stent |  | 10 Another Boston Scientific Site Certifies to ISO 14001:2004 |
|  | 6 An Interview with U.S. Physician Douglas Adler, M.D. |  | 11 Boston Scientific Receives Recognition for Packaging Innovation |
|  | 6 Boston Scientific Agrees to Acquire Xlumena |  | 12 Next-generation Order Management With eOrder Web Portal |
|  | 7 Close the Gap Hosts Symposium on Pancreatic Cancer |  | 13 The SpyGlass System Helps Pave the Way for Reimbursement |
|  | 7 Employees Do Their Part through Fundraising | | Advocacy Plays an Important Role in U.S. Hospital Reimbursement |

Case Studies

- | | |
|--------------------------------------------------------------|-------------------------------------------------------------|
| 14 SpyGlass DS Direct Visualization System | 18 Captivator™ II EMR |
| 15-16 Resolution Clip | 19 CRE™ Wireguided Balloon Dilator, WallFlex Duodenal Stent |
| 17 Resolution Clip, TWISTER® PLUS Rotatable Retrieval Device | 20-21 Expect™ and Expect Slimline Needles for EUS FNA |

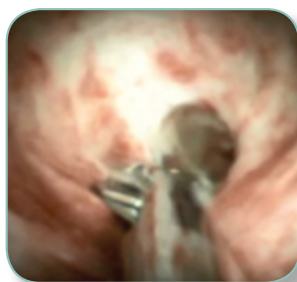Opt-in to receive ACCESS magazine electronically as well as email updates on new products, indications and resources. Visit www.bostonscientific.com/endo-access-subscribe.

New SpyGlass DS System *Brings a Sharper Focus to Cholangioscopy*

2015 brings significant digital imaging enhancements to the only single-operator, single use biliary and pancreatic duct direct visualization tool. The SpyGlass™ DS System not only features digital imaging clarity and stability, but other improvements promote ease of use, allowing for greater efficiencies in setup and procedures that will benefit clinicians and patients alike.

This spring, Boston Scientific is set to revolutionize cholangio-pancreatography again. Cleared for use by the FDA in mid-January and CE Mark approval received in March, the SpyGlass DS System introduces digital imaging clarity and stability to biliary and pancreatic duct visualization where prior commercially available technologies offered fiber-optic resolution and workflow inefficiencies. The new system will feature not just a clearer picture, but a bigger one with a 60% wider field of view.

“The image was beautiful,” said Columbia University practicing gastroenterologist and Assistant Medical Professor Amrita Sethi, M.D., after using SpyGlass DS for the first time. “It’s very clear. There are details that we’ve certainly never seen before.”



Another big change to the original system is that the fiber-optic probe has been eliminated with the integration of a digital imager that is fully integrated into the catheter — making the entire SpyScope™ Catheter a single-use device — so there is a savings in costs and resources for reprocessing. Moreover, image degradation associated with multiple-use fiber-optic probes becomes a thing of the past. Physicians appreciate this not only because of the better image quality but also because they don’t have to take the time to pre-load the fragile fiber-optic probe and their staff no longer have to worry that they will break the probe during set-up.

“Not having a separate fiber-optic channel is outstanding and is also going to make life so much easier and less stressful for our nurses and techs who worried about breaking this probe during set-up,” said Steven Edmundowicz, M.D., chief of endoscopy for Barnes-Jewish Hospital in St. Louis.

RE-ENGINEERING THE SPYGLASS SYSTEM FOR DIGITAL IMAGING

Building the next-generation system meant retaining its best design features while retrofitting it with cutting-edge technology. Boston Scientific Research and Development (R&D) Director John Hutchins explained, “To be truly innovative and have an impact on cholangioscopy, we sat down with physicians from around the world who had used the original system to learn what improvements they wanted most in the new system.”

“The image was beautiful. It’s very clear. There are details that we’ve certainly never seen before.”

— Amrita Sethi, M.D.
Assistant Medical Professor
Columbia University

Since the development of the original SpyGlass System, there has been an evolution of camera sensor technology in the marketplace, providing the opportunity to incorporate a high-resolution digital imager into the DS System. Imagine how the cameras in your smartphones and tablets have improved over the last five years, to the point where point-and-shoot digital cameras are a nearly obsolete artifact, gone the way of the typewriter and rotary telephone.

When the SpyGlass System came on the market, Boston Scientific Global Director of Pancreatico-biliary Marketing Ryan Hartman points out, “digital cameras probably could have delivered imaging as sharp as the SpyGlass™ DS System is doing today. But at the time, those sensors were cost-prohibitive for a very small disposable scope and would have driven the cost beyond the reach of most practices. Today, these costs have decreased significantly, making the integration of this technology feasible while enabling more patients to have access to this technology.”

Physician feedback from early cases indicates that the SpyGlass DS System’s digital imaging and significantly wider field of view is revealing details unseen before, such as vascularity and mucosal structures in biliary and pancreatic ducts.

A ‘PLUG-AND-PLAY’ SETUP

Digital + **Simple** = **DS**

Digital clarity is only half the story: While the “D” stands for “digital,” the “S” speaks to “simplicity” – the other major upgrade to the SpyGlass System. Setup time and effort were frequently cited as areas for improvement. “From the beginning of this project, my team has been focused on making sure that the setup of the SpyGlass DS System is going to be so easy and transparent that it’s just like pulling out any other device during ERCP for physicians,” said Kurt Geitz, Boston Scientific research and development vice president.



The SpyGlass DS System integrated digital controller has a single plug connection.

Reducing the setup time was addressed by implementing automatic software calibration of the camera’s illumination, focus and white balance. Those processes previously represented multiple, manual steps for nurses and technicians. “I think that maybe one of the more

profound impacts of the new SpyGlass DS System will be on our nurses and our techs,” said Robert Hawes, M.D., founder of The Center for Interventional Endoscopy at Florida Hospital in Orlando.

Added Dr. Sethi, “The SpyGlass DS System doesn’t take up a lot of room. It doesn’t involve moving an entire unit in and out of a procedure room. And I think that now we’ll perform a larger portion of our exams using cholangioscopy rather than cholangiography.”

CLINICAL IMPACT

“From a physician and patient standpoint,” said Boston Scientific Group Product Manager Anthony Borrelli, “clearer imaging data using the SpyGlass DS System could potentially lead to swifter decisions and care path options compared to standard ERCP procedures. The possible scenarios include a patient needing surgery could know they need it sooner, and those whose diagnoses cannot be addressed with surgery could seek alternative treatments earlier in their disease progression.”

“I could potentially treat gallstone disease in that first setting and spare the patient a second procedure down the road.”

— **Gregory Cote, M.D.**
Associate Professor of Medicine
Medical University of South Carolina

Physicians themselves say that more efficient ERCP with better imaging will improve their ability to treat patients. “I could potentially treat gallstone disease in that first setting and spare the patient a second procedure down the road,” said Charleston, S.C. practicing gastroenterologist Gregory Cote, M.D., who is also associate professor of medicine at the Medical University of South Carolina. “I think that adds tremendous value to the system as well as, of course, to the patient and their family.”

Added Dr. Hawes, “My hope is that the new SpyGlass DS System will reduce the number of repeat procedures. We’ll be able to plug and play and do cholangioscopy whenever it’s indicated rather than placing a stent and coming back at a later date. So, hopefully, that will improve efficiency and ultimately lower costs and improve outcomes.”

In 2007, the launch of the SpyGlass Direct Visualization System revolutionized cholangioscopy and pancreatoscopy with the first single-operator system enabling direct visualization and optically guided diagnostic and therapeutic procedures inside the biliary, pancreatic and hepatic ducts. For the two decades prior to this, cholangioscopes required two operators and were very fragile, making the procedure possible but difficult.

Since its introduction, more than 1,000 sites are using the system globally, more than 50,000 cholangioscopies have been performed worldwide and more than 300 clinical papers have been published about the procedure in peer-reviewed journals, with over 100 of them devoted to the SpyGlass System.



AN INTERVIEW WITH

Bryan Gilpin, director of supply chain solutions at Boston Scientific, talks about how working with health care providers has changed, what change management has to do with it and why having skin in the game makes Boston Scientific a partner for the long haul.

Q What are some of the changes you are seeing in the health care provider supply chain?

Managing costs isn't new, but as providers prepare to operate in a changing health care environment, they've been working to better understand those costs. At the same time, they have been looking for ways to reduce spending without impacting patient care, and in many cases make improvements to managing a patient's care and overall experience. The Affordable Care Act has been a driving force in providers wanting more from their suppliers and device manufacturers are an important part of the equation. Providers are looking for suppliers that are willing to work with them – to be true collaborators – to develop solutions that can help them deliver the best quality care at the lowest possible cost.

Q How is Boston Scientific responding to these changes?

We've been working for a long time to help our customers manage aspects of their supply chain. So we had a pretty good idea of the kinds of things our customers wanted help with but we knew we had to start by listening and understanding their real pain points. Having too much inventory, spending too much time managing inventory, chasing orders, not having enough lab or shelf space – these are issues shared by many of our customers. In order to address these needs, we formalized some of our services, offering structured programs. In a relatively short time, we've seen good results with programs such as inventory optimization, order consolidation and vendor-managed inventory.

Q Has the role of the supply chain manager changed?

We believe so. We see managers in this area taking a more holistic approach to managing costs. For those with supply chain responsibilities, device cost is always a concern, but there's more to it. These managers are shifting their focus to achieve cost savings through efficiencies – in ordering, delivery, inventory and overall simplification of their supply management. In addition, supply chain managers want to provide service and value to their internal customers, which means coming up with solutions that allow clinicians to spend less time on things like inventory and more time focused on patient care.

Q What's been the biggest challenge in implementing supply chain improvement programs?

Change can be difficult for any organization. One customer that we've been working with to reduce inventory has made significant

progress. Before the work, the lab was crowded and product was stacked high. It could be difficult to find something or to know how much they actually had on hand — not uncommon for any lab.

Now there are fewer devices on the shelf so it's easy to see what you have which, in turn, means spending less time managing product and more time to plan. Sounds good, but initially people were uncomfortable with the fact that they didn't have a lot of product around. It took time for them to see how it worked and how the new way of doing things could benefit them. It's really a culture shift so it's important to recognize that people embracing new ways of doing things is an important part of the process.

To date, we've had positive feedback from customers, yet we think we've just scratched the surface when it comes to the types of things that can help drive efficiencies and add value.

Q Why should hospitals work with Boston Scientific to improve their supply chain?

The supplier-provider relationship has changed in health care. Hospitals are defining value in new ways and they want more of it. We're very much in line with this because we've been providing supporting services for a long time. We've never been about just taking orders and delivering product. And now, we've taken it to the next level.

Importantly, we don't take a one-size-fits-all approach. Some customers simply want help assessing their situation but they have resources to implement a solution. Others want help in addressing specific areas such as order consolidation. For multi-center hospitals with a main point of distribution, order consolidation can be an area with great potential for efficiency and cost savings.

Boston Scientific's interests are aligned with the provider's interests in that we are both vested in the lab's success. Different from external consultants, we don't leave when the project is done. We have been and we are in the relationship for the long term.

NEW Website for Services and Programs

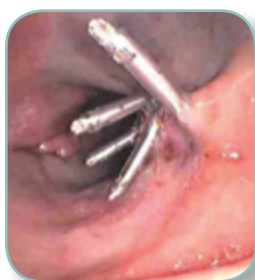Boston Scientific offers services and programs with the goal of helping customers achieve their patient care and operational efficiency goals. **Visit www.bostonscientific.com/gastroservices** to learn about supply chain optimization, reimbursement, customer service, patient education and more.

To learn more about Boston Scientific's Supply Chain Optimization services, email us at SupplyChainOptimization@bsci.com or visit **www.bostonscientific.com/gastroservices**.

Resolution Clip is First Hemostasis Clip to Receive Clearance for Prophylactic Clipping

Over the last ten years, the Resolution™ Clip has helped change the way physicians practice hemostasis and treat their patients. Until recently, the Resolution Clip was cleared for hemostasis, endoscopic marking, closure and anchoring jejunal feeding tubes. Boston Scientific continues to innovate in the hemostasis space and in 2014 was able to secure the expanded indication for prophylactic clipping.

More than 5 million Resolution Clips have been placed and more than 220 peer-reviewed articles have been published over the last 10 years. Overall, the Resolution Clip has impacted more than 2.5 million patient lives.




The Resolution Clip received FDA 510(k) clearance and CE Mark approval for the expanded indication of hemostasis for prophylactic clipping to reduce the risk of delayed bleeding post lesion resection, further increasing the options available for patients. It is currently the only hemostasis clip on the market cleared for prophylactic clipping.

A retrospective study by Rex et al. found that prophylactic clipping of large post-polypectomy-induced ulcers can **reduce the risk of delayed bleeds from 9.7% to 1.8%**¹. Clipping to reduce the risk of delayed bleeding may result in potential cost-savings by helping patients avoid hospitalization, blood transfusions, repeat colonoscopies and surgical procedures.¹

1) Liaquat H, Rohn E, Rex DK. Prophylactic clip closure reduced the risk of delayed postpolypectomy hemorrhage: experience in 277 clipped large sessile or flat colorectal lesions and 247 control lesions. *Gastrointest Endosc* 2013 Mar;77(3):401-7.

Largest Study Published on WallFlex Fully Covered Esophageal Stent



Dr. Alessandro Repici et al. authored the largest study on the WallFlex™ Fully Covered Esophageal Stent, which was published in the December 2014 issue of the *Digestive and Liver Disease Journal*. The goal of the study was to assess the clinical (recurrent dysphagia) and technical success using the WallFlex Fully Covered Esophageal Stent in patients with dysphagia due to primary inoperable esophageal cancer.

The study found that placement of a WallFlex Fully Covered Esophageal Stent resulted in safe and effective palliation of malignant dysphagia. The **median dysphagia scores improved from "3" (ability to swallow liquids only) to "1" (ability to eat some solid food)** at both fourteen days and four weeks after stent placement. Analysis found there was no association between the rate of complications and/or recurrence of dysphagia with either prior or subsequent radiotherapy and/or chemotherapy.

3 (swallow liquids only)

(eat some solid food) **1**

The article, *Management of Inoperable Malignant Oesophageal Strictures with Fully Covered WallFlex Stent: A Multicentre Prospective Study*, is available at <http://www.journals.elsevier.com/digestive-and-liver-disease/>.



AN INTERVIEW WITH U.S. PHYSICIAN

Douglas Adler, M.D., from the University of Utah Hospital, speaks with Boston Scientific about the benefits of physician-controlled wireguided cannulation and using a short-wire system.

Q Why do you use a physician-controlled guidewire system?

I use a physician-controlled wire system mostly because it gives me the most freedom. By myself, I can control the scope, sphincterotome and the guidewire all at the same time. I can manipulate much more quickly and much more accurately than if I had to relay verbal instructions to an assistant or technician.

I think the big issue is efficiency. I can go much faster if I'm controlling the wire. The thought goes directly from my brain to my hand with no intermediary. In a lot of situations, during cannulation or in the case itself, I want to adjust the position of the wire, move it from one duct to the other – I can do that very quickly with a few seconds of fluoroscopy. This technique dramatically shortens the procedure time.


Q How long have you been using this technique?

As a trainee, I used short wire and physician-controlled wire techniques and I recognized very quickly that my cannulation success rates were higher when I was controlling the wire. I've been doing physician-controlled guidewire cannulation the entire time I've been in practice.

Q How has it changed your practice?

We always want to minimize fluoroscopy time for the patient and we try to adhere to the "alara" principal (as low as reasonably allowable) when exposing patients to radiation. Physician-controlled guidewire cannulation helps reduce the amount of time that I'm using fluoroscopy because I know exactly when the wire is moving and when it's not.

Boston Scientific Agrees to Acquire Xlumena



In April, Boston Scientific announced it signed a definitive agreement to acquire Xlumena, Inc., a venture-backed medical device company that develops, manufactures and sells minimally invasive devices for endoscopic ultrasound (EUS)-guided transluminal drainage of targeted areas within the gastrointestinal tract.

Xlumena products include the AXIOS™ and HOT AXIOS™ Stent and Delivery Systems. The AXIOS Stent and Delivery System has received U.S. Food and Drug Administration clearance and is the world's first stent designed for endoscopic ultrasound-guided transluminal drainage of symptomatic pancreatic pseudocysts. The next-generation HOT AXIOS Stent and Delivery System incorporates cautery into the delivery of the AXIOS Stent. Both systems have CE Mark approval for facilitating transgastric or transduodenal endoscopic drainage of pancreatic pseudocysts or the biliary tract. These products are currently sold in select countries in Europe.

The AXIOS System technology platform broadens the Boston Scientific portfolio of minimally-invasive approaches to treat pancreatic pseudocysts, which may be caused by pancreatitis (acute or chronic inflammation of the pancreas), pancreatic ductal obstruction or trauma. The acquisition of Xlumena with these innovative EUS devices demonstrates Boston Scientific's commitment to providing a robust EUS capability that plays a role in both diagnosis and treatment.

CAUTION: The Hot AXIOS Device is pending 510(k) review. It is not available for sale in the United States.

Close the Gap Hosts Symposium on Pancreatic Cancer

As part of its initiative to support Pancreatic Cancer Awareness Month, Close the Gap, a Boston Scientific health equity program, hosted a symposium to help educate employees about the deadly disease. More than 140 people attended the November 17 event held at the company's headquarters in Marlborough, Massachusetts, to learn about pancreatic cancer and the various organizations supporting research and clinical trials.

Employees heard from Dr. Priya A. Jamidar, professor of medicine, digestive diseases, and director of endoscopy at the Yale School of Medicine; Dana Dornsife, president and founder of Lazarex Cancer Foundation; as well as Cheryl Yacovone and Sandra Nagale, two Boston Scientific employees who lost family members to the disease. A special guest presenter was Jack Andraka, a teen innovator who developed a potential screening test for pancreatic cancer.

STUDENTS CONNECT INNOVATION WITH PATIENT CARE

Local Marlborough high school students who participate in the **STEM program (students interested in science, technology, engineering and math)** and raised money for pancreatic cancer research were also invited. They had the opportunity to hear from Andraka who shared his experience as a STEM student, and explained his innovative work, how he came up with his ideas and how a pancreatic cancer diagnosis of a close family friend



From left to right: Dr. Priya A. Jamidar, Jack Andraka, Cheryl Yacovone, Dana Dornsife

inspired him to want to make a difference. He talked with students about the challenges he faced when trying to get the necessary resources for his work and how young people can make significant contributions by pursuing a career in science. Andraka is also an author and his book, *Breakthrough: How One Teen Innovator Is Changing the World*, became available in March.

Afterward, students attended a product fair to learn how Boston Scientific technologies are used to diagnose and treat the symptoms of pancreatic cancer and other gastrointestinal diseases.



Participants in the No Shave November fundraiser.


Employees Do Their Part through Fundraising

Close the Gap spearheaded numerous activities throughout 2014 to help raise awareness about pancreatic cancer. Employees took part in various fundraising initiatives, raising more than \$42,000 in support of The Lustgarten Foundation and its mission of advancing research related to pancreatic cancer. The Boston Scientific Close the Gap team also sponsored pancreatic cancer research walks and employees participated in these walks in Naperville, Ill., Jones Beach, N.Y., Denver, Colo., and Boston, Mass.

New Patient Education Card

Now available!

A new tool for physicians to help educate patients about pancreatic diseases and treatment options. To order, contact your Boston Scientific representative.



Left to right: Dr. Jacques Van Dam, Dr. Yao Fang, Dr. Wu Qi and Dr. Li Peng.

China Summit Marks the Start of *Physician Training Program*

The China ERCP Training Summit, held November 7, 2014, marked the end of a week of activities and served as the official kick-off of the training program designed to develop highly skilled endoscopists focused on using the latest advancements in GI technologies to better serve patients throughout China. More than 50 representatives participated, including the president of the Chinese government's Ministry of Health, president and board members of the Chinese Society of Digestive Endoscopy (CSDE), along with an expert panel of physicians from Europe and the U.S.

At the event, an agreement of commitment was signed and a ceremony provided the opportunity for participants to stress the importance of education, training and best-practice sharing. The group made recommendations for the 2015 program including requests for global faculty involvement and advanced overseas ERCP exchange programs. In addition, they emphasized the importance of future collaboration among China and U.S. GI societies under the guidance of Professor Zhao-Shen Li, president of the CSDE.

The panel of experts included Dr. Marco Bruno from the Erasmus Medical Center, The Netherlands, and from the U.S., Dr. Stuart Sherman, Indiana University, Dr. Jacques Van Dam, University of Southern California, and Dr. Michael Kochman, University of Pennsylvania. The week included a number of meetings and events, including a one-day session held at the Boston Scientific Institute for Advancing Science in Shanghai where the discussion focused on designing a professional training program. Participants from Boston Scientific included Troy Lengel, global marketing manager, Duncan Meldrum, vice president of marketing for Asia, Middle East and Africa, and Rich Cohen, global director of market development.

After the summit, each physician traveled to a major teaching hospital in China to gain a better understanding of the current state of trainee education and to observe cases. The facilities visited included Shanghai Changhai Hospital, Xijing Hospital, the first Hospital of Lanzhou University, Nanfang Hospital and the Beijing Friendship Hospital.



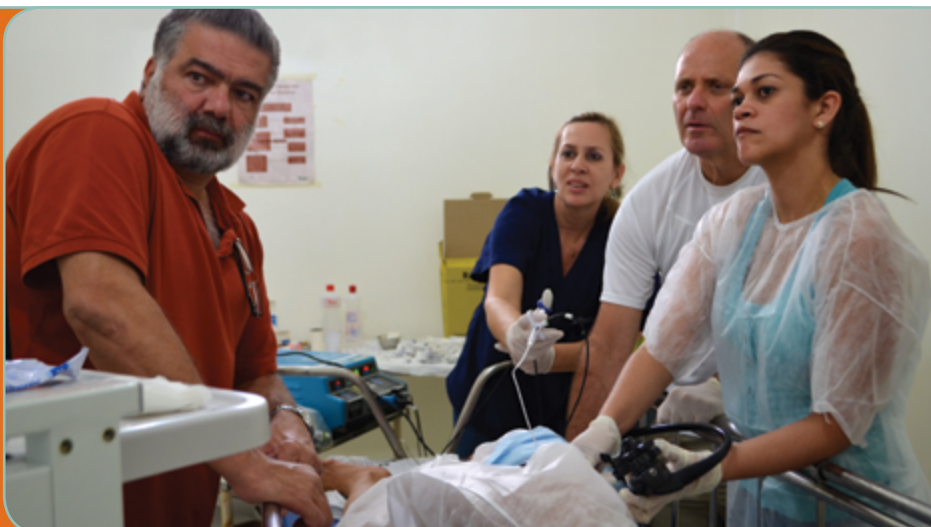Professor Zhao-Shen Li delivering a lecture on the significance of ERCP procedural adoption in China.



From left to right: Troy Lengel, Dr. Stuart Sherman, Duncan Meldrum, Dr. Michael Kochman, Professor Marco Bruno, Dr. Jacques Van Dam, Rich Cohen

Screenings are Part of Campaign to Deliver Care to Remote Region of Brazil

More than 2,000 men and women in the City of Belterra (State of Pará), a remote region of Brazil, will undergo screenings for colorectal cancer – the third most common cancer in Brazil. The Hospital Sírío Libanês is spearheading the campaign to bring medical care to this remote area of the country.



The initiative will include several trips to Belterra during a two-year period. The goal is to develop the skills necessary to perform these types of procedures so local physicians and nurses can continue to provide care to the region. Marcelo Averbach, M.D. from Sírío Libanês Hospital, and Angelo Ferrari, M.S., Ph.D, from Albert Einstein Hospital, coordinated the team of endoscopists, residents and medical students who would perform the procedures and provide training to local clinicians.

Boston Scientific is supplying equipment and devices necessary to perform diagnostic and therapeutic colonoscopies and endoscopies. In addition, the Boston Scientific Endoscopy team in Brazil has supported the development of the project over the past year. This included working with key opinion leader physicians on training requirements, managing logistics, and helping to educate the indigenous population about colon cancer and other gastrointestinal diseases.

From left to right: Dr. Angelo Ferrari, RN Aldenir Fresca, Dr. Marcelo Averbach, and Dr. Márcia Tatianna Fernandes Pereira perform a colonoscopy on a patient during one of the recent trips to Belterra.

New Online Tools for Patients and Physicians

With funding from Boston Scientific, the National Pancreas Foundation has developed two videos to educate patients about endoscopic retrograde cholangiopancreatography and endoscopic ultrasound fine-needle aspiration. The videos, along with other information on pancreatic diseases, are intended to provide easy-to-understand information for patients, and to enhance communication between patients and their physicians.

The EUS FNA video is now available for viewing
www.pancreasfoundation.org or
www.animatedpancreaspatient.com.



Another Boston Scientific Site *Certifies to ISO 14001:2004*

In 2013, Boston Scientific completed certification of 12 of its major global operations sites to the internationally recognized ISO 14001:2004 Environmental Management System (EMS) standard. As one of the company's five-year sustainability goals, the work continued with the certification of its Marlborough, Massachusetts Headquarters in late 2014. The Marlborough campus, which is also home to Boston Scientific's Endoscopy business, includes four buildings with an overall footprint in excess of 600,000 square feet.

Certification to the standard was performed by an independent third party, which confirmed that the location's EMS conformed to the standard, and identified goals and targets to reduce the environmental footprint of operations occurring both on and off site. Key 2014-2015 targets include reducing greenhouse gas emissions through adoption of renewable energy and completion of energy efficiency projects, increasing recycling and reuse of waste generated at the site, and reducing air emissions associated with commuting by advancing public transportation use.

EMPLOYEE PARTICIPATION MAKES THE DIFFERENCE

Dave Pierce, president of Boston Scientific's Endoscopy business and executive sponsor of the initiative, played an active role in gaining support for the work among the various functions and groups across the campus. "Employee support was crucial to the initiative's success and their participation in helping to improve the site's environmental performance did not go unnoticed by members of the certifying body," said Leonard Sarapas, corporate director of environment, health and safety.

The Marlborough site's current plan involves the installation of a **1.5 mega-watt solar array** on site, including **electric car charging stations** to reduce greenhouse gas emissions and encourage the use of low-emission vehicles. Started in late 2014, the project is slated to go live in early-to mid-2015. Along with the site's combined heat and power plant, these renewable energy technologies will **meet over half of the site's energy needs**.

With a large employee population at the Marlborough site, food-related waste was a significant component of materials that could not be recycled. In early 2015, the site launched a campus-wide composting initiative. Simple in concept but complex in implementation, the program involved investigating and selecting compostable food containers and utensils for the cafeteria, making major modifications to waste collection systems, completing arrangements with a licensed composting facility, as well as educating employees about the change and their part in properly managing this waste. By year end, the site expects to substantially reduce its waste levels and improve its overall recycling rate.

Boston Scientific's 1.1-million-square-foot Customer Fulfillment Center in **Quincy, Mass.** has earned the U.S. Environmental Protection Agency's (EPA) **Energy Star Certification**. This marks Boston Scientific's first U.S. EPA certification and demonstrates the company's dedication to energy efficiency and sustainability.

The **Kerkrade, Netherlands** European Distribution Center was recognized with a **Lean and Green Award**, issued by the Dutch Connekt Program, for progress in reducing environmental impacts by improving the site's energy efficiency.

Now available for download—

Boston Scientific's 2014
Global Sustainability Report.

www.bostonscientific.com

Boston Scientific Receives Recognition for Packaging Innovation

In 2014, Boston Scientific was recognized on both the U.S. and world stages for its design of the tear tab closure strip. The company set out to create a better restocking aid and, while doing so took the opportunity to create something that would also benefit its customers.



The tear tab is used on the new SpyGlass™ DS Direct Visualization System scope carton.

The Institute of Packaging Professionals (IoPP) awarded Boston Scientific the **AmeriStar Award** for the tear tab closure strip. Judges for the IoPP evaluated and analyzed packages from 13 categories (such as medical device, beverages and cosmetics) based on **package innovation, sustainability, protection, economics, performance, and marketing.**

Boston Scientific also received the **WorldStar Award** from the World Packaging Organization – considered the pre-eminent international award in packaging. WorldStar Awards are presented only to those packages which, having

already won recognition in a national competition, are compared by an expert panel of judges to similar packages from around the world. Awards are based on the judges' consensus that a package is superior in its own right and better in its class in execution or innovation by comparison. In good company, Boston Scientific received recognition among companies such as Proctor & Gamble, Kellogg and 3M.

A SMALL CHANGE CAN HAVE A BIG IMPACT

“Our customers helped define the issues,” explained Amie Marshall, Boston Scientific packaging and lead engineer on the design team. The existing strip was made of a strong flexible material but could be difficult to open. The new tear tab closure enables one-handed opening and helps pull the carton tuck flap out for easy opening.

Customer feedback was an important part of the development, explained Marshall. Of the 73 customers surveyed, all agreed the new tear tab was easy to open. The tear tab also received high marks for helping to open the carton's tuck flap and having no tear strip to throw away separately as it remains adhered to the carton. Based on the overwhelmingly positive feedback, Boston Scientific plans to use the tear tab on all product cartons that have the original strip.

“Our customers helped define the issues.”

— Amie Marshall
Packaging and
Lead Engineer,
Boston Scientific

Next-generation Order Management with eOrder Web Portal



Customers who do not have electronic data interchange (EDI) materials management systems can enjoy many of the same benefits of electronic ordering that hospitals with substantial enterprise IT system capabilities afford, thanks to eOrder, Boston Scientific's online purchasing portal. These benefits include electronic order confirmations, ship notifications, purchase-order template management for frequently ordered items, online transaction histories and around-the-clock order placement.

Introduced in 2009 for U.S. customers and driven by customer interest in going paperless, eOrder has grown steadily, according to eCommerce Team Supervisor John Davidian. Some customers, after trying it a few times, become loyal "diehards" who won't go back to ordering via paper, faxes and phone calls.

In addition, ecommerce systems like eOrder are one way to practice Lean management principles – a currently popular idea among materials management professionals looking to pare down processes so they take up minimum organizational bandwidth. "It can be a significant gain in efficiency," Davidian says.

BUT IS IT FOR ME?

What type of customer is best suited to giving eOrder a try?

- You are open-minded to a new system and are ready for a change from paper-based routines.
- You do not have an EDI system, yet you want its convenience as well as its automatically updated online data trail.
- Reducing the time spent printing, faxing and confirming orders, as well as talking on the phone with customer service, are priorities for your organization.

Experienced eOrder users can populate templates and place orders in seconds. "They're buying products straight out of their item master; it's not really a shopping scenario," Davidian notes. "We want to provide customers with what they want and nothing more, because the bells and whistles can be distracting. It's a very streamlined experience."

Other features of eOrder include the capability for multiple users to access the site simultaneously; access to online catalogs; UPS™ and FedEx™ package tracking links embedded in email shipping notices; and no additional fees for registering for or using the system. Customers who try eOrder and decide it is not for them can simply go back to traditional fax, paper or phone methods.

ELECTRONIC ORDERING, SAME CUSTOMER SERVICE

eOrder makes the procurement process more efficient and automated, yet it features the same rigorous standards of customer service that all Boston Scientific customers receive, regardless of order method. These standards drive the call center, including a system that gets callers on the line with a person within eight seconds of answering.

"Our goal is to deliver a positive experience every time a customer contacts Boston Scientific Customer Service. We are proud of our answer and accuracy rates, and the industry recognition we've received as a result," says Andrew Coughlin, manager of the eCommerce and Call Center departments. Recognition includes awards from J.D. Power and Associates and Omega NorthFace, "Additionally, services such as eOrder enable us to give our customers options and the services that help them improve how they do business," he adds.

Order accuracy is also a focus; the customer service team doesn't just check its own work, but the customer's, too. The ecommerce team added an analytics system to detect orders that aren't consistent with a customer's previous patterns. When those are flagged, it trips a quick callback to confirm the customer meant to order those items and correct any problems. Boston Scientific saved 30,000 line items of errant shipments in 2014, which saved customers aggravation in the form of wasted time and materials as well as return shipping and restocking costs.

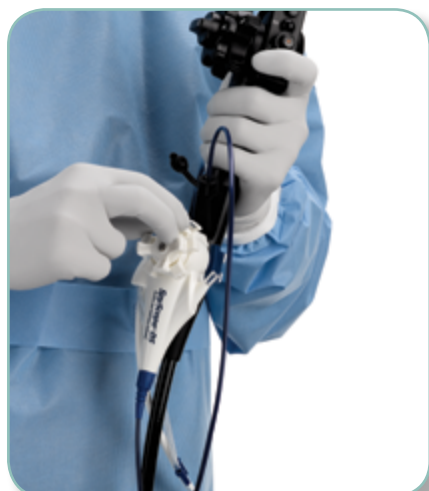eOrder system requirements: A Web browser such as Explorer, Chrome, Firefox or Safari, and an Internet connection.

☎ Call **877-272-3340** for more information, or

✉ email **BSCWebConnectInquiry@bsci.com**.

eOrder registration can take up to seven days to complete.

The SpyGlass System Helps *Pave the Way for Reimbursement*



In 2007, cholangioscopy was rarely offered for a number of reasons. The available technology was difficult to use and labor-intensive. Moreover, although the procedure had been in existence for years, it was done so rarely that there were no codes available to describe it to insurers and there was no set payment rate. As a result, providers and patients were at financial risk when cholangioscopy was performed. “The lack of reimbursement was definitely a barrier to adoption,” said Boston Scientific Director of Health Economics and Reimbursement Maria Stewart. “Hospitals are understandably reluctant to take on technologies or procedures where they can’t be sure they’re going to get paid.”

Part of the problem was that there was no cholangioscopy-specific procedure (CPT®¹) Code. Inconsistencies in reimbursement were tied to the fact that cholangioscopy had to be billed to a miscellaneous “catch-all” code related to the larger set of endoscopic procedures.

Upon learning about the SpyGlass™ System and seeing its clinical impact, the GI specialty societies determined that the device would enable cholangioscopy to be performed more frequently. Based on the available clinical evidence and the improvements in deliverability afforded by the original SpyGlass System, the societies petitioned the American Medical Association (AMA) to establish a cholangioscopy-specific CPT Code, which became effective in January 2009.

The Centers for Medicare and Medicaid Services (CMS) subsequently assigned cholangioscopy-specific payment for both physicians and facilities in their annual Medicare fee schedules. As is often the case in U.S. health care billing and coding landscape, commercial payers followed CMS’s lead.

“Private insurance companies had something to benchmark,” Stewart said. “Once we got a code and appropriate physician and facility fees assigned, it was much easier for commercial payers to pay for cholangioscopy.” **In 2014, as part of a broader effort to “bundle” payment for procedures typically performed together, cholangioscopy payment for facilities was bundled together with payment for the ERCP procedure(s) it always accompanies. Facility payment rates for ERCP were increased to accommodate the bundling. Physicians continue to be paid separately for cholangioscopy when it is reported.**

The clinical impact of the SpyGlass DS System has the potential to eclipse the trailblazing of the original SpyGlass, Stewart thinks. The improved imaging, simpler setup, and the potential to impact diagnostic and therapeutic pathways and outcomes are well aligned with the health reform goals espoused in the Affordable Care Act (ACA): improved access, efficiency and quality of care, and reduced overall cost of care.

¹ CPT Copyright 2014 American Medical Association. All rights reserved. CPT is a registered trademark of the American Medical Association. Applicable FARS/DFARS Restrictions Apply to Government Use. Fee schedules, relative value units, conversion factors and/or related components are not assigned by the AMA, are not part of CPT, and the AMA is not recommending their use. The AMA does not directly or indirectly practice medicine or dispense medical services. The AMA assumes no liability for data contained or not contained herein.


Advocacy Plays an Important Role in U.S. Hospital Reimbursement

Boston Scientific regularly collaborates with gastroenterology societies and government agencies to advocate for appropriate reimbursement and to address regional and national reimbursement challenges.

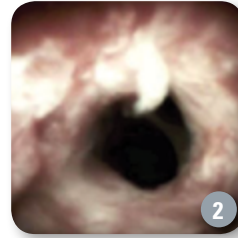
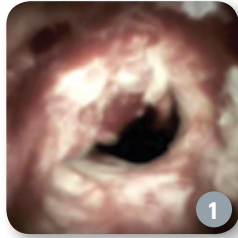
During a 2015 webinar hosted by Boston Scientific on coding and Medicare reimbursement changes for gastroenterology, Glenn Littenberg, M.D., MACP, chair, Practice Management Committee ASGE, and chief medical officer, inSite Digestive Health Care, commented:

“The major reason that the ERCP stenting and GI stenting [payments] went up is that based on persuasive logic from Boston Scientific and from our GI Societies going to visit CMS, we had them understand that the resource cost of stents [was] substantially greater than what had been paid and they agreed to change the APC assignments ... resulting in a substantial increase in the reimbursement of these.”

Diagnosing Local Spread of Hilar Cancer Using the SpyGlass DS System



CASE PRESENTED BY:
ISAAC RAIJMAN, M.D., FACP, AGAF, FASGE
 CHI St. Luke's Hospital
 Digestive Associates of Houston
 Houston, Texas, USA



PATIENT HISTORY AND ASSESSMENT

A 79-year-old male presented to his family practitioner with yellowing of the skin, dark urine, pruritus and progressive weight loss. He was found to have abnormal LFTs. Abdominal ultrasound showed dilated intrahepatic ducts. An MRCP revealed a mid-bile duct stricture. He underwent an ERCP at the referring institution at which time a mid bile duct stricture was diagnosed. Brush cytology and fluoroscopy-guided biopsies revealed atypical cells. A stent was placed with clinical improvement. A repeat ERCP was performed with the same results. However, the removed stent was sent to pathology, revealing adenocarcinoma. The patient was deemed a surgical candidate.

PROCEDURE

The patient was seen for consultation to better determine the location of the stricture. An ERCP was performed that revealed a 1cm stricture located 2cm distal to the biliary confluence. Cholangioscopy using the SpyGlass™ DS Direct Visualization System was performed, revealing a malignant stricture in the CHD extending to the RHD and LHD and further into the LHD 1cm to the confluence (**Figures 1 and 2**). The more proximal IHDs were not involved.

OUTCOME

The patient was not considered a candidate for surgery and has undergone chemotherapy. The SpyGlass DS System was used in this case to establish a diagnosis and to determine the exact location of the stricture as well as to rule out local extension of the disease beyond the observed cholangiographic changes.

Patient management was altered based on the findings using the SpyGlass DS System because we were able to determine that the patient was not a candidate for surgery. This saved the unnecessary costs and potential risks associated with an unsuccessful surgery.

OVERALL RECOMMENDATIONS

I would recommend using the SpyGlass DS System in any ERCP performed for abnormal LFTs and imaging performed for biliary stricture in which there is a question as to:

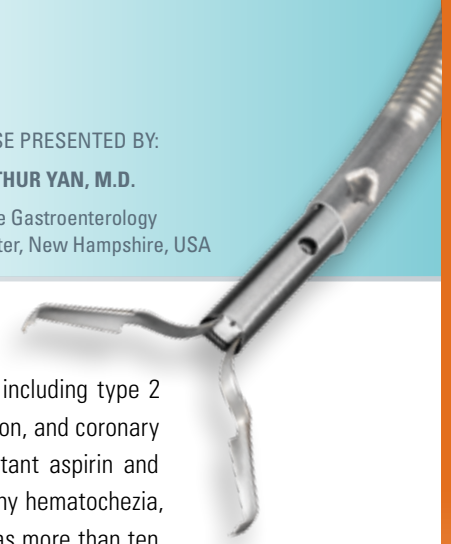
- The cholangiographic image
- The need for targeted tissue acquisition
- Recognizing unidentified pathology such as that causing decreased visualization of biliary anatomy
- Identifying unclear luminal filling defects
- Determining local extent of a malignancy



Prophylactic Clipping to Manage Potential Post-polypectomy Bleeding for Patients Using Antiplatelet Agents



CASE PRESENTED BY:
ARTHUR YAN, M.D.
Core Gastroenterology
Exeter, New Hampshire, USA



PATIENT HISTORY

A 61-year-old male presented for a screening colonoscopy. He had an extensive cardiac history including type 2 diabetes, hypertension, hyperlipidemia, sick sinus syndrome with permanent pacemaker implantation, and coronary artery disease requiring placement of a drug-eluting stent seven years ago. He takes concomitant aspirin and clopidogrel, for which the latter has been held for seven days prior to the procedure. He denies any hematochezia, melena or abdominal pain. He has no family history of colonic neoplasms. His last colonoscopy was more than ten years ago for which he had an inadequate bowel preparation.

PROCEDURE

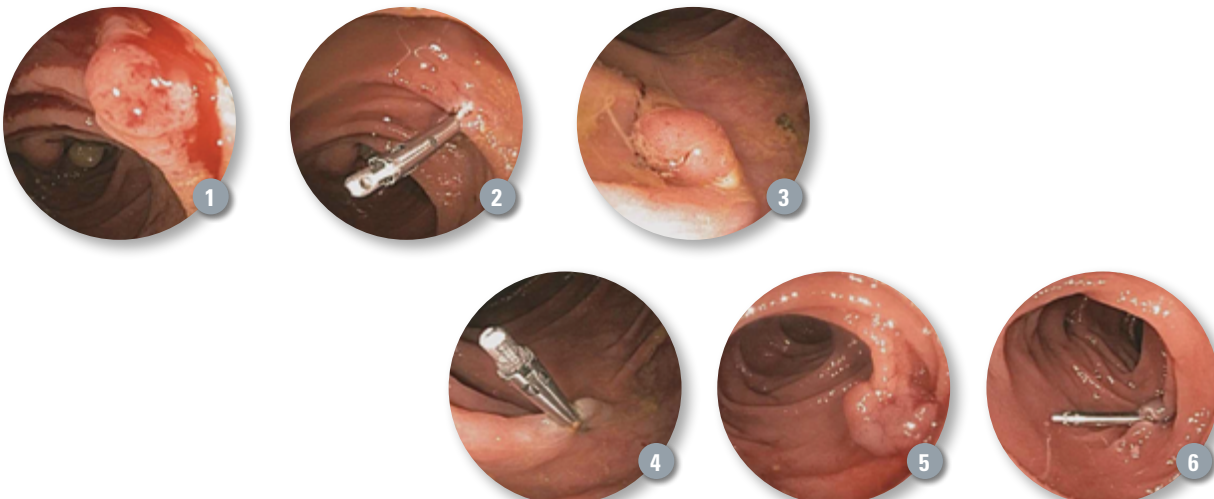
The colonoscopy revealed small non-bleeding internal hemorrhoids, a normal terminal ileum, and diverticulosis extending from the ascending colon to the sigmoid colon. A total of six presumed adenomatous polyps were found during the procedure. One of these polyps in the ascending colon was friable on contact (**Figure 1**). The 7mm polyp was resected with a Captiflex™ Oval Snare using cautery. Given concurrent use of aspirin and clopidogrel and the risk for delayed post-polypectomy bleeding due to thermal injury in the right colon, a Resolution™ Clip was successfully deployed at the polypectomy site (**Figure 2**). A second 7mm polyp in the ascending colon was encountered (**Figure 3**). This was also resected with the Captiflex Oval Snare using thermal cautery, and followed by placement of a Resolution Clip (**Figure 4**). A third pedunculated polyp measuring 12mm was similarly resected and retrieved from the proximal transverse colon with a Captiflex Oval Snare using electrocautery (**Figure 5**). A Resolution Clip was also placed the base of the polypectomy site (**Figure 6**).

POST PROCEDURE

The patient resumed his clopidogrel that evening and continued to take his aspirin. The results from the pathology laboratory confirm the resected polyps to be tubular adenomas. No post-polypectomy bleeding was encountered. On one week follow-up, the patient reported feeling well with no melena or hematochezia.

DISCUSSION

Delayed post-polypectomy bleeding can occur in up to 2% of patients, and is significantly higher in patients on dual antiplatelet agents. Post-polypectomy ulceration and thermal necrosis from electrocautery may injure the deeper layers of the colonic wall, resulting in delayed hemorrhage from blood vessels of the submucosa. The resection of large polyps as well as removal of polyps from the right colon can carry an increased risk of post-polypectomy hemorrhage. **As bleeding complications can occur anytime from one week to one month post-procedure, prophylactic placement of the Resolution Clip may help minimize this risk.**



Removal of Sessile Polyp in the Cecum During Endoscopic Mucosal Resection



CASE PRESENTED BY:

ABHIJIT KULKARNI, M.D., FASGE

Associate Professor
Temple University School of Medicine
Director, Therapeutic Endoscopy
Allegheny General Hospital, Pennsylvania, USA

PATIENT HISTORY

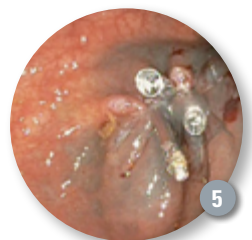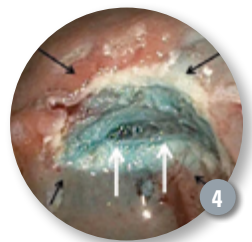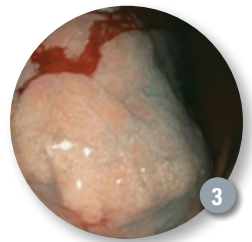
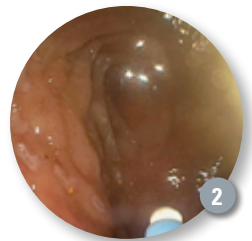
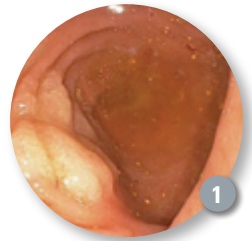
A 68-year-old female in good health and at average risk of developing colorectal cancer underwent a routine screening colonoscopy. A 20mm sessile polyp in the cecum was found with a benign appearance (**Figure 1**). She was referred to our institution for therapeutic polypectomy.

PROCEDURE


Colonoscopy was performed using a standard colonoscope. A sessile polyp with a central depression (Paris classification II-a + II-c) was identified. The margins of the lesion were demarcated (**Figure 2**) using argon plasma coagulation. A solution containing isotonic saline was injected into the submucosa below the polyp using a 25 Gauge Interject™ Contrast Single Use Injection Therapy Needle Catheter. The polyp lifted uniformly, indicating absence of submucosal invasion (**Figure 3**). The polyp was then ensnared using a flexible 27mm Sensation™ Single-Use Snare and removed en bloc. No post-polypectomy bleeding was noted although close inspection of the base suggested a defect extending to the muscularis propria (**Figure 4**). The patient was then rotated to position the post-polypectomy site in a nondependent location. Three Resolution™ Clips were then placed in succession to appose the margins of the polypectomy defect (**Figure 5**). The patient was observed for two hours in the recovery room and discharged. Follow-up conversation with the patient the next day confirmed a continued asymptomatic state. Final pathology revealed a non-dysplastic sessile serrated adenoma. Treatment includes a follow-up colonoscopy in six months.

CONCLUSION

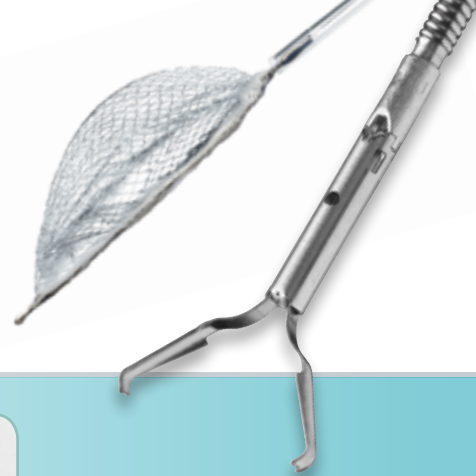
This case highlights a technique for endoscopic management of large sessile polyps (lateral spreading tumors) in the relatively thin-walled cecum. **Using an array of readily available endoscopic accessories, the polyp was resected entirely, obviating the need for surgical intervention. A potential perforation was rapidly identified and managed nonoperatively with a favorable outcome.**



Post-polypectomy
(black arrows
denote polypectomy
margin; white
arrows denote
possible deeper
defect)



TWISTER PLUS Rotatable Retrieval Device and Resolution Clip for Closure of Bleeding Gastric Lesion after Endoscopic Resection



CASE PRESENTED BY:

NEIL R. SHARMA, M.D.

Director of Advanced Interventional Endoscopy
Medical Director of GI Oncology Program
Physician Service Line Leader, Parkview
Comprehensive Cancer Center
Volunteer Assistant Professor of Medicine,
Indiana University, Indianapolis, Indiana, USA



SCOTT PATRICK HARRISON

2nd Year Medical Student
Indiana University School of Medicine
Indianapolis, Indiana, USA

PATIENT HISTORY

An 86-year-old male patient with a medical history of chronic kidney disease, reflux, stroke, coronary artery bypass surgery, atrial fibrillation on Coumadin™ anticoagulant, diabetes, appendectomy and cholecystectomy was referred for an upper endoscopy and a colonoscopy (which was essentially unremarkable).

The patient had a drop in baseline hemoglobin from 14.2 to 11.0 on routine labs and during an upper endoscopy was found to have active bleeding from a benign-appearing gastric mass. The mass was an unexpected finding during the upper endoscopy and although he has a history of reflux, he did not have ulcers. Biopsies showed reactive gastropathy with associated mild inflammation. A test for *H. pylori* came back negative.

PROCEDURE

During upper endoscopic evaluation, the mass and surrounding area were evaluated with high-definition white light and narrow-band imaging. An antral nodule was found at 12 o'clock to 2 o'clock above the pyloric channel and was actively bleeding (**Figure 1**). The nodule was approximately 2cm and almost mass-like.

It had an active bleed and likely represents a focal area hypertrophic change of a gastric fold due to inflammation from portal hypertensive gastropathy and peristalsis. There was also surrounding GAVE (gastric antral vascular ectasia).

Radial endoscopic ultrasound (EUS) was also performed (showing lesion to be mucosal based). Active bleed and failed prior attempt at cautery substantiated the need for endoscopic resection of the mass-like antral nodule. Submucosal injection was performed using a specific mixture of methylene blue/epinephrine/hetaspan/saline. Once adequate lift was achieved, the specimen could be resected en bloc.

The nodule was excised with snare using specific electrocautery settings. An en bloc resection was achieved (**Figure 2**). A TWISTER® PLUS Rotatable Retrieval Device was used to retrieve the specimen (**Figure 3**). The design of the net allowed for the basket to spin into position, decreasing the time to facilitate the capture of the specimen for pathology. The specimen was pinned to a board and sent to pathology for examination and diagnosis (**Figure 4**).

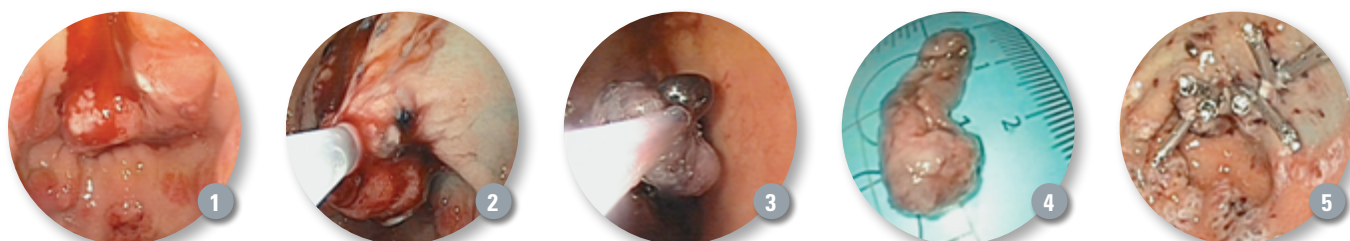The defect was treated with argon plasma cautery (APC) of surrounding GAVE. Wattage 30, set at a flow rate of 0.7, and force settings were used with APC. To close the defect and control bleeding, a total of seven Resolution™ Clip Devices were placed (**Figure 5**). The design of the Resolution Clip facilitated closure because of its ability to open and close and reposition into the appropriate position. This allowed for a tight closure of the large endoscopic mucosal resection (EMR) defect with relative ease.

POST PROCEDURE

The patient did well without any complications and was placed on oral iron supplementation. Final pathology showed regenerative polyp with slight inflammation and focal erosion.

PATIENT OUTCOME

After three months, the patient had an improvement in follow-up hemoglobin; his hemoglobin was stable at 14.2. A repeat esophagogastroduodenoscopy showed the lesion to be healed with normal appearing overlying mucosa in its place. The clips had appropriately fallen off as the area healed. A small amount of GAVE persisted which responded to retreatment with APC.



Tubulovillous Adenoma with Intramucosal Adenocarcinoma



CASE PRESENTED BY:
BRIDGER W. CLARKE, M.D.
 South Hills Gastroenterology
 Clairton, Pennsylvania, USA

PATIENT HISTORY

A 76-year-old male presented for routine colonoscopy after a stool hemocult returned positive at his primary care physician's office. Colonoscopy revealed a flat, carpet-like polyp extending from the anal verge to 8cm and involving two-thirds of the rectal circumference (**Figure 1**). Biopsies demonstrated tubulovillous adenoma. After discussing management options including surgical versus endoscopic resection, the patient opted to pursue endoscopic removal.

PROCEDURE

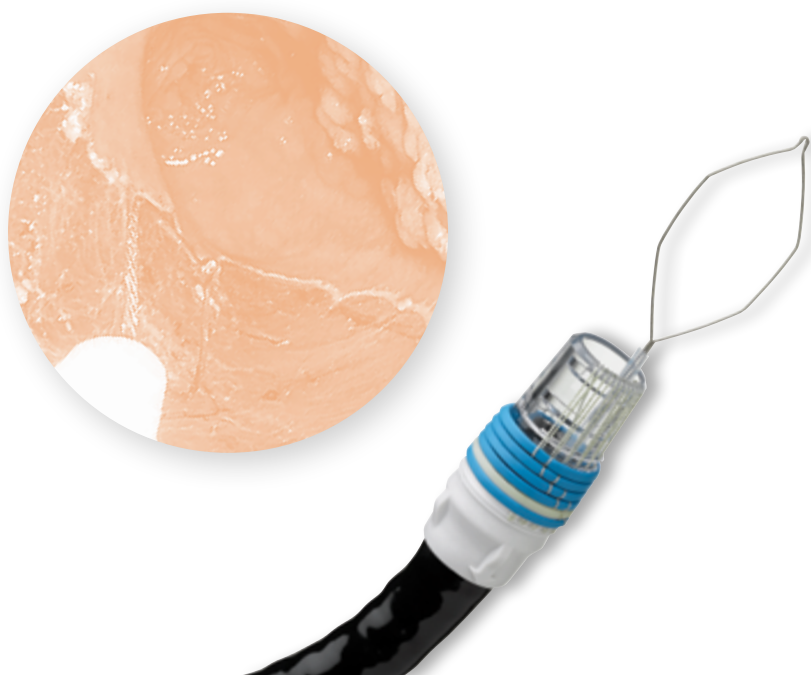
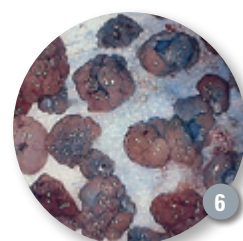
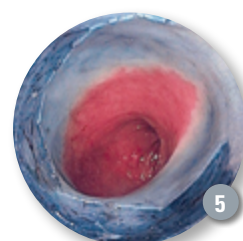
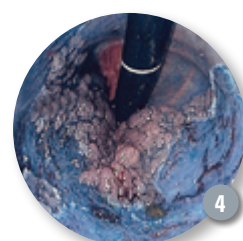
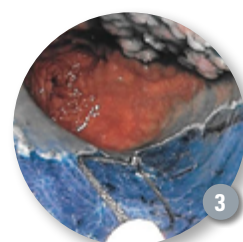
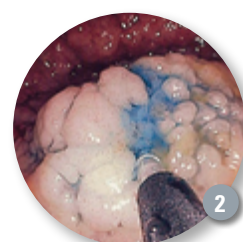
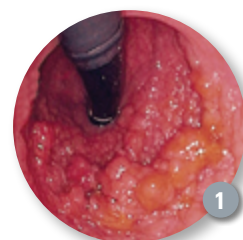
Propofol sedation was administered by an anesthesiologist. An Interject™ Contrast Single-Use Injection Therapy Needle Catheter was used for injection into the submucosal layer deep beneath the polyp to aid in EMR (**Figure 2**). Piecemeal resection was performed using both Captivator™ II 25mm (**Figure 3**) and 10mm Snares. The majority of the resection was performed in the retroflexed position. A 10mm Captivator Snare and Radial Jaw™ Hot Biopsy Forceps were used to carefully clear all visible adenomatous tissue around the dentate line (**Figures 4 and 5**). Over forty resected specimens were sent for pathologic review, which demonstrated tubulovillous adenoma with high-grade dysplasia and one area of intramucosal adenocarcinoma (**Figure 6**).

OUTCOME

A CT scan and rectal endoscopic ultrasound were negative for lymphadenopathy or evidence of metastatic disease. Our recommendation was to undergo close surveillance; however, given the common practice of complete resection for this condition, the patient ultimately decided to undergo abdominoperitoneal resection after consulting with an outside surgeon. Pathology from the resected rectum was completely clear of any adenomatous and cancerous tissue.

CONCLUSION

This case demonstrates the effectiveness of wide-field endoscopic mucosal resection for dysplastic polyps and intramucosal adenocarcinoma, with definitive pathologic confirmation on the resected rectum. Unfortunately, the lack of general awareness of the effectiveness of this technique may lead to unnecessary surgery and morbidity.



A Gastroenterologist and Surgical Oncologist Collaborate to Relieve Gastric Outlet Obstruction



CASE PRESENTED BY:

**DONALD GARROW, M.D.
AND STEVEN GOLDIN,
M.D., PH.D., FACS,
MPH, CPH**

Fawcett Memorial Hospital
Port Charlotte, Florida, USA

BACKGROUND

Gastric outlet obstruction (GOO) is a common symptom in patients with cancer involving the distal stomach, proximal duodenum and pancreatic head. With respect to pancreatic adenocarcinoma located in the head of the pancreas, patients will sometimes present with the clinical symptoms of nausea, vomiting, bloating, malnutrition and dehydration approximately fifteen percent of the time, indicating a potential underlying gastric outlet obstruction from the pancreas tumor.

Often patients receive imaging studies that reveal an obstruction and a surgeon is consulted for possible gastrojejunostomy. In certain situations, however, surgery is not an option based on the patient's nutritional status. The collaboration between a gastroenterologist and surgeon is very important and it is now possible to manage many gastric outlet obstructions endoscopically using duodenal stents.

PATIENT HISTORY

A 68-year-old man presented to the hospital with the symptoms of nausea, vomiting, abdominal pain and bloating – indicative of an underlying gastric outlet obstruction. A computed tomography scan of the

abdomen with contrast revealed a 2.8cm head of pancreas mass with no evidence of biliary obstruction. An experienced pancreatic surgeon collaborated with the local therapeutic gastroenterologist to determine the best course of treatment and to address the underlying symptoms of gastric outlet obstruction. Given the patient's adequate functional status, the surgeon requested an interventional gastrointestinal consult to consider placement of a luminal duodenal stent.

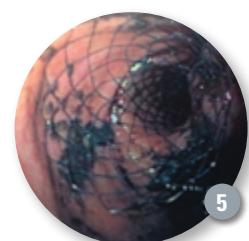
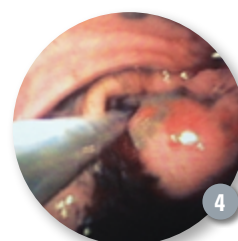
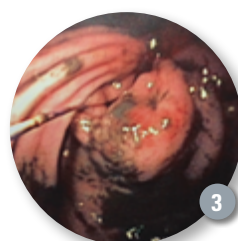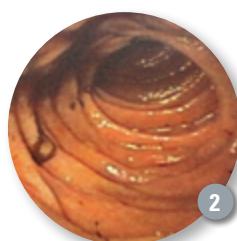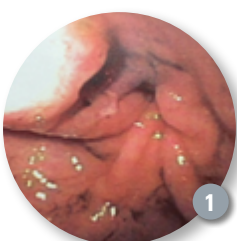PROCEDURE

After determining the patient was a suitable candidate to attempt luminal duodenal stenting, an EGD was performed. Retained gastric food and fluid were found during the EGD. The items were immediately suctioned to decrease the risk of aspiration. The pyloric valve and duodenal bulb were found to be compressed by the invading pancreatic tumor (**Figure 1**). The therapeutic adult upper endoscope was unable to traverse the pyloric and duodenal bulb stricture initially. A standard 0.035 inch guidewire was passed with fluoroscopic guidance across the stricture into the second portion of the duodenum (**Figure 3**). An 18-20mm CRE™ Dilation Balloon was fed across the guidewire and utilized to inject contrast within the duodenal lumen, allowing for adequate assessment of the length and degree of malignant luminal stricturing.

The balloon was then utilized to safely and effectively dilate the stricture in stepwise fashion. Afterward, the endoscope was advanced with ease across the strictured area with aid of the guidewire. A healthy appearing duodenum was observed in the second portion of the duodenum (**Figure 2**). The guidewire was left in place (**Figure 3**) with the retraction of the endoscope to the proximal portion of the stricture area. A WallFlex™ Duodenal Stent measuring 22mm x 90mm was placed over the wire (**Figure 4**) and deployed through the scope under direct and fluoroscopic visualization (**Figure 5**).

CONCLUSION

A multidisciplinary approach may be utilized to optimize treatment in advanced cancer patients. **In this case, a surgical oncologist's collaborative approach with an interventional gastroenterologist was the key to successful management of this patient. Being able to effectively place an intraluminal duodenal stent in a malignant gastroduodenal stricture alleviated the multiple refractory upper gastrointestinal symptoms, providing a means to maintain adequate weight and nutrition.**



A Case of EUS-Guided Liver Biopsy



CASE PRESENTED BY:

AMITPAL SINGH JOHAL, M.D.

Associate Director, Division of Gastroenterology
Director of Endoscopy, Geisinger Medical Center
Danville, Pennsylvania, USA

PATIENT HISTORY

A 55-year-old male with a medical history of Barrett's esophagus (last EGD for Barrett's surveillance was four years ago), morbid obesity, diabetes and hypertension was seen in the Hepatology clinic for an initial evaluation of elevated liver function tests. The patient's recent lab work showed an ALT of 80, AST of 75 and normal bilirubin and alkaline phosphatase levels. Initial serologic work up for intrinsic liver disease was unremarkable. A right upper quadrant ultrasound was performed which showed a non-dilated common bile duct, normal gallbladder without stones or sludge, normal pancreatic head and a hyperechoic liver consistent with fatty infiltration. The patient was referred for an upper endoscopy for Barrett's surveillance along with an endoscopic ultrasound for EUS-guided liver biopsy.

PROCEDURE

The patient underwent an EGD and EUS under propofol sedation monitored by a nurse anesthetist. Initially, the upper endoscopy was performed which revealed a 2cm tongue of salmon-colored mucosa consistent with COM2 Barrett's esophagus. No nodules or mucosal irregularities were seen with white light and narrow-band imaging. Surveillance biopsies were obtained. Next, the linear echoendoscope was advanced into the proximal stomach. The celiac artery was identified. The scope was torqued counterclockwise 90 degrees, then the big knob was turned up to identify the left lobe of the liver. The 19ga Flex Expect™ Slimline Needle was advanced into the liver after confirming no intervening vessels by color Doppler (**Figure 1**). The stylet was removed and full suction (20cc) was attached to the needle. Seven to ten "to and fro" movements were performed. The needle was removed and the stylet was used to express the entire specimen into a formalin cup. Visual inspection was done confirming multiple cores of tissue.

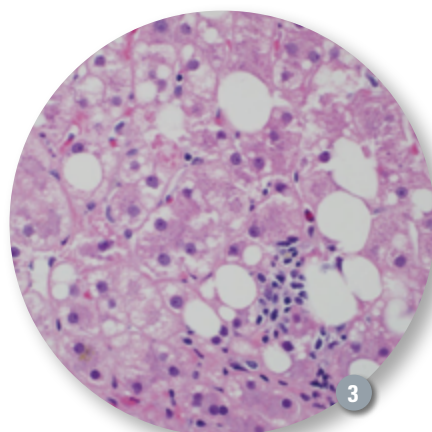
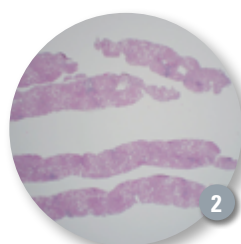
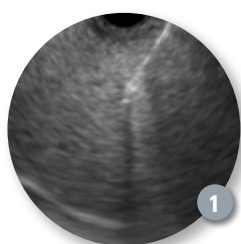
The linear echoendoscope was then advanced into the distal duodenal bulb. The echoendoscope was torqued approximately 180 degrees with knob up to identify the right lobe of the liver. Again, the 19ga Flex Expect Slimline Needle was used to procure the liver specimen in the same manner as described previously.

OUTCOME

An EGD revealed stable non-dysplastic Barrett's esophagus. EUS-guided liver biopsy revealed steatohepatitis with moderate steatosis and portal fibrosis with focal interface and perivenular perisinusoidal fibrosis (stage 2 of 4) (**Figures 2 and 3**). The patient was referred to a nutrition and weight management clinic.

CONCLUSIONS

Endoscopic ultrasound-guided liver biopsy (EUS-LB) is emerging as an exciting and innovative addition to the gastroenterologist's armamentarium. Through endosonographic guidance, a 19ga (non Trucut) FNA needle is used to procure the specimen from one or both lobes of the liver. There are several advantages of this technique: (1) easy access to both right and left lobes to avoid sampling error; (2) simultaneous evaluation of the pancreas, gallbladder, common bile duct and other structures; (3) concurrent EGD to evaluate upper digestive disorders such as Barrett's esophagus; (4) offers sedation/analgesia for increased comfort, reduced anxiety, and negates the need for breath hold; (5) potential cost savings in patients who require an EGD or EUS in addition to the EUS-LB, since both can be performed in the same setting; (6) allow real-time Doppler ultrasound to avoid small vessels. **The 19ga Flex Expect Slimline Needle is well suited for this application as it easily passes into the right lobe of the liver, despite a looped and angulated scope position.**



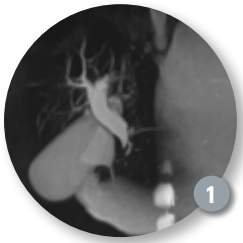EUS FNA Diagnosis of Adenocarcinoma of the Ampulla Facilitated Palliative Treatment Using a Duodenal Stent



CASE PRESENTED BY:

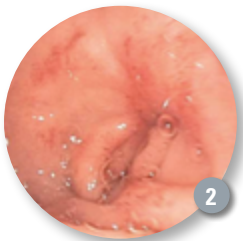KUMAR KRISHNAN, M.D.

Assistant Professor of Medicine
Houston Methodist Hospital
Division of Gastroenterology
Houston, Texas, USA



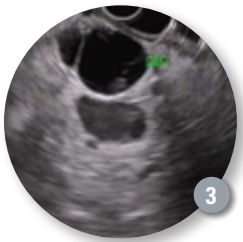
PATIENT HISTORY

A 76-year-old female with multiple cardiac comorbidities presented with two weeks of progressive nausea and vomiting. She had an associated 10-pound weight loss. On admission, she was noted to be dehydrated. Initial laboratory evaluation revealed abnormal liver enzymes. An MRCP (Figure 1) was performed.



An MRI revealed a dilated common bile duct with tapering at the ampullary region. The pancreatic duct was normal. No masses or lesions were noted in the pancreas. No stones were apparent in the common bile duct.

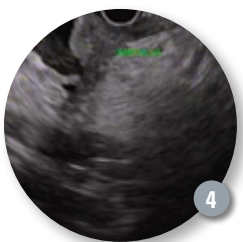
Initial upper endoscopy revealed a tight obstruction in the duodenal bulb (Figure 2). A standard gastroscope was unable to advance. Biopsies were unrevealing.



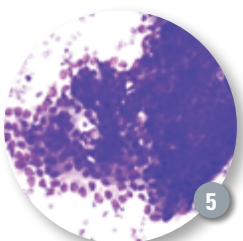
PROCEDURE

A linear echoendoscope was then placed in the duodenal bulb. A markedly dilated common bile duct was noted (Figure 3).

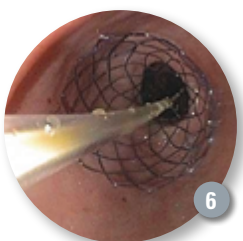
The linear echoendoscope was torqued to follow the distal common bile duct. While no pancreas mass was identified, the ampullary region was prominent and irregular in appearance (Figure 4). The pancreas duct was normal in appearance. The ampullary region was targeted for EUS-guided FNA using an Expect™ Slimline Needle (25 gauge). Three passes were made. On-site cytologic evaluation revealed adequacy and final cytologic evaluation revealed adenocarcinoma of the ampulla (Figure 5).



The patient was determined not to be a surgical candidate, so the patient was prepared for duodenal stent placement. To accomplish this, a 0.035 inch x 450cm Hydra Jagwire™ Guidewire was advanced through a balloon catheter. The duodenum was deformed as a result of the tumor. Careful manipulation of the wire eventually yielded deep enteral access. The balloon catheter was passed over



the wire and contrast was injected to confirm intraluminal access to the distal small bowel. The balloon catheter was removed and a 23mm x 9cm WallFlex™ Stent was easily advanced through the stricture and deployed under fluoroscopic guidance (Figure 6). A percutaneous transhepatic cholangiostomy tube was placed by interventional radiology for biliary decompression.



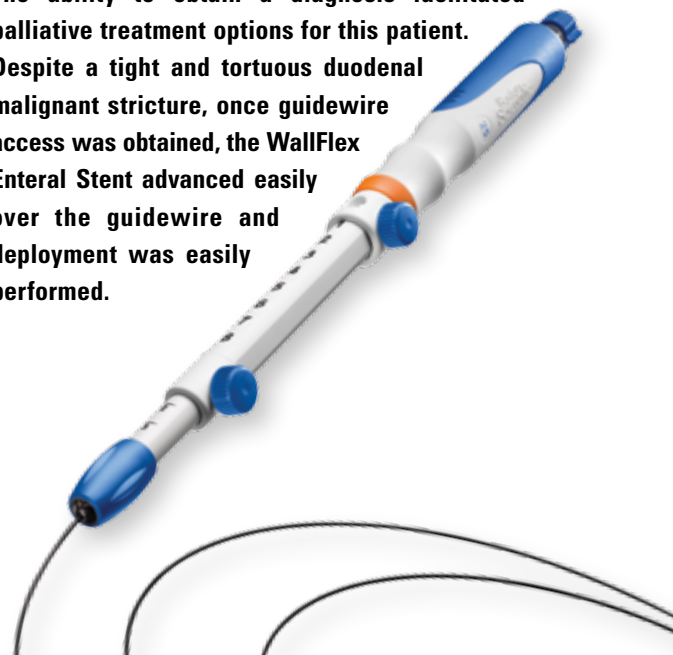
the wire and contrast was injected to confirm intraluminal access to the distal small bowel. The balloon catheter was removed and a 23mm x 9cm WallFlex™ Stent was easily advanced through the stricture and deployed under fluoroscopic guidance (Figure 6). A percutaneous transhepatic cholangiostomy tube was placed by interventional radiology for biliary decompression.

OUTCOME

Post procedure, the patient was able to take oral nutrition and gradually advanced her diet. Liver enzymes gradually improved, and she was discharged to home.


CONCLUSION

Evaluation of the pancreatic head and ampullary region is challenging in the context of malignant duodenal obstruction. EUS can oftentimes aid in obtaining a diagnosis. The location of the echoendoscope in relation to the tumor requires a substantial amount of elevator use and torque for adequate positioning to facilitate FNA. The 25 gauge Expect Slimline FNA Needle passed without any difficulty despite the significant amount of angulation from the elevator. The echo density of the needle allowed for easy visualization of the needle during FNA, as care was taken not to puncture the common bile duct. **This patient was a poor operative candidate due to existing cardiac comorbidities. The ability to obtain a diagnosis facilitated palliative treatment options for this patient. Despite a tight and tortuous duodenal malignant stricture, once guidewire access was obtained, the WallFlex Enteral Stent advanced easily over the guidewire and deployment was easily performed.**



News and New Devices

- The new **SpyGlass™ DS Direct Visualization System** offers improved visualization and is designed to optimize procedural efficiency and productivity. The system's integrated digital sensor provides superior imaging, four times the resolution and a 60 percent wider field of view than the first-generation system. It also offers physicians an integrated controller that fits on a standard ERCP cart for improved accessibility and a 'plug-and-play' setup.



- The **Jagwire™ High Performance Guidewire** is now available in three additional configurations. The guidewire features striped markers and tungsten-filled tips for visualization, Endo-Glide™ Coating to promote smooth tracking and enhanced tactile sensation, and straight or angled tips to accommodate physician preference. Three new sizes have a distal tip of .025" and are available with a standard angled round tip, a stiff straight round tip, or a stiff angled round tip to provide physicians with even more options.

- The **Captivator™ EMR** is Boston Scientific's first device specifically designed for ligation-assisted endoscopic mucosal resection (EMR) of the upper gastrointestinal (GI) tract. EMR ligation may be used to treat many diseases of the upper GI tract such as squamous neoplasma and Barrett's esophagus. Benefits of the device include 360-degree cap visualization to assess lesions and the ability to pass 7Fr tools with the device in place – an important option in managing complications. The Captivator EMR Device includes the Captivator EMR Band Ligator, Captivator EMR Snare and Captivator EMR Pathology Kit.



➤ Colon Cancer Prevention Tool Kit Now Available

A new tool kit to help educate patients on colorectal cancer screening and prevention is now available for physicians and nurses to share with patients. The kit includes a Blue Hope Prevention card, news articles, fact sheet, risk assessment card and a brochure co-branded with the Colon Cancer Alliance. Contact your Boston Scientific representative for copies of these and other helpful patient tools. Learn more at www.preventcrc.com.



➤ Strategic Alliance Expands Reach in China

Boston Scientific signed a strategic alliance with Frankenman Medical Equipment Company of Suzhou, China, a recognized leader with deep local market expertise in the China surgical devices market. The alliance will enable Boston Scientific to help expand the adoption of less-invasive endoscopic procedures in China, which has the potential to lead to better patient outcomes and reduced health care costs.

The paper used for this product catalog has been produced in accordance with:



ACCESS magazine was produced in cooperation with several physicians. The procedures discussed in this document are those of the physicians and do not necessarily reflect the opinion, policies or recommendations of Boston Scientific Corporation or any of its employees.

Results from case studies are not predictive of results in other cases. Results in other cases may vary.

Indications, Contraindications, Warnings and Instructions for Use can be found in the product labeling supplied with each device.

Caution: Federal (U.S.) law restricts this device to sale by or on the order of a physician.

CAUTION: The law restricts these devices to sale by or on the order of a physician. Information for the use only in countries with applicable health authority product registrations.

WARNING: The safety and effectiveness of the WallFlex Biliary Stent for use in the vascular system has not been established.

CAUTION: The HOT AXIOS Device is pending 510(k) review. It is not available for sale in the United States.

TWISTER® PLUS is a trademark of Horizons International Corp.

Distributed by Boston Scientific Corporation, Marlborough, Massachusetts; manufactured by Horizons International Corp., Heredia, Costa Rica.

All trademarks are the property of their respective owners.

©2015 Boston Scientific Corporation or its affiliates. All rights reserved.

DINEND2344EA

ENDO-311901-AA May 2015

Boston Scientific